



Exodonty associated with immediate implantation in Aesthetic Area

Luciana Fortes Tosto Dias^{1,2}, Eduardo Costa Figueiredo Passos^{1,2}, Álvaro José Cicareli^{1,2}

¹ Unorp-University Center North Paulista, Sao Jose do Rio Preto, Sao Paulo, Brazil.

² UnB - Universidade de Brasília / University of Brasilia / School of Health Sciences, Brasilia, Distrito Federal, Brazil.

*Corresponding author Email: moniele-med@hotmail.com

DOI: <https://doi.org/10.34256/mdnt2133>

Received: 14-05-2021; Accepted: 06-06-2021; Published: 09-06-2021

Abstract: Introduction: In the scenario of extraction associated with immediate implantation in the aesthetic area, tooth extraction is common in the daily clinical practice of the dentist, with the main causes of caries, periodontal disease, and coronal-radicular fractures. All extractions must be performed with precise indication, given defined prosthetic planning, thus avoiding an imbalance in the occlusion, swallowing, and aesthetics of the patient. **Objective:** To carry out a systematic review on the main approaches to extraction associated with immediate implantation in the aesthetic area. **Methods:** Followed a systematic review model (PRISMA). The search strategy was carried out in the PubMed, Embase, Ovid, Cochrane Library, Web Of Science, and Scopus databases. The quality of the studies was based on the GRADE instrument and the risk of bias was analyzed according to the Cochrane instrument. **Results:** A total of 134 studies were found that were submitted to the eligibility analysis and, after that, 41 studies of high to medium quality and with risks of bias were selected that do not compromise the scientific basis of the studies. According to the main literary findings, the use of the technique of installing immediate implants, after extraction, requires planning and care in the management of soft tissues, to correct aesthetic sequelae. The use of precise and minimally traumatic techniques enabled satisfactory and functional aesthetic results, as well as improving the patient's aesthetics and self-esteem. **Conclusion:** The immediate implant placement procedure after tooth extraction preserves bone height and thickness, reduces treatment time and cost, in addition to maintaining the gingival architecture, being important for the aesthetic success of future prosthetic rehabilitation. Also, it presents success rates comparable to implants in fully healed edges, the extraction must be done in a minimally traumatic way, to preserve the maximum bone tissue. The horizontal defects present after the installation of the immediate implant (gaps), if they are less than or equal to 3mm, will heal with complete bone filling. However, if they are larger than 3mm, bone graft material and/or membrane should be used so that there is bone healing.

Keywords: Exodontics, Immediate dental implant, Dental extraction, Minimally traumatic extraction, Aesthetics

1. Introduction

In the scenario of extraction associated with immediate implantation in the aesthetic area, tooth extraction is common in the daily clinical practice of the dentist, with the main causes of caries, periodontal disease, and coronal-radicular fractures [1]. All extractions must be performed with precise indication, given defined prosthetic planning, thus avoiding an imbalance in the occlusion, swallowing, and aesthetics of the patient [2]. Thus, the professional must be able to offer the patient all options for rehabilitation after extraction.

The choice for rehabilitation with implants has been growing and, to be carried out, it needs alveolar bone preservation at the implant site and adequate gingival contour, especially in aesthetic regions. These requirements can and should be planned from tooth

extraction, and for that purpose, there are minimally traumatic extraction techniques (MTE) [3].

In this context, the conventional extraction technique performed with levers and forceps exerts horizontal movements and/or rotations in the tooth to be extracted enough to rupture the collagen fibers resulting in bone expansion or fracture of the buccal bone plate. Thus, it is evident that conventional extraction traumatizes the alveolar bone to a considerable extent [4]. Thus, techniques to enable a less traumatic tooth extraction have been available in recent decades, these techniques aim to perform a tooth extraction in the vertical direction, preserving alveolar bone [5]. In this sense, the principle of the new systems for extractions is that there is a minimum of bone expansion and trauma in the alveolus, eliminating forces in the horizontal direction [5].

In this regard, some techniques have emerged with this principle, either with special forceps or with sophisticated and highly ingenious systems. These new devices perform a traction force in the axial direction of the tooth root to be extracted, and if applied successfully, it should minimize bone trauma, resulting in the rupture of periodontal fibers without bone expansion [6]. However, the new techniques and instruments for MTE still need to be analyzed, as little research has evaluated the success rate and limitations of these devices.

In this context, the growing technological development of implantology presents dental professionals with a challenge, which consists in the search for an aesthetic gingival architecture, which satisfies the professional's objectives as planned and also the result expected by the patient who is submitted to this type of treatment [7]. Several authors have reported the immediate installation of implants in the socket of extracted teeth. The reason for this procedure is to reduce the treatment time and cost, preserve the height, alveolar bone thickness, and soft tissue dimension, promoting bone-implant contact [8-12].

In a study with 16 years of follow-up of patients, the survival rate for implants placed immediately after tooth extraction was 96%, which should therefore be a procedure of choice due to its good prognosis [13]. Indications for immediate implant extraction and installation are teeth with irreversible failures in endodontic treatment, teeth with advanced periodontal disease, root fractures, and advanced cavities below the gingival margin. In addition, teeth with suppuration or extensive periapical infection are not candidates for extraction and immediate installation of the implant [12,14].

Despite this, some studies report very satisfactory results related to the immediate installation of implants, even in infected sites [10-14]. In this respect, some factors are considered determinants for obtaining a positive result in the treatment of implant installation placed immediately in the extraction of the tooth socket, such as the preservation of the bone margins of the socket during extraction, the primary stability of the implant in the apical portion of them along the walls of the alveolus, careful control of the tissue flap, the narrow closure adapted to the implant neck and meticulous control of the plaque throughout the healing period [12].

Also, other steps and care must be taken to obtain the ideal position of the implant such as the

alignment of the implant relative to the tooth to be restored and the position of the implant head must be located 3 mm apically apex to the cement-cement junction of the adjacent tooth, to allow uniformity of the margin of the cementum junction and accommodation of the abutment and prosthesis subgingivally [15]. This dimension must be respected so that there is space for biological distances (sulcular epithelium, junctional epithelium, and conjunctive insertion). Failure to respect these dimensions will cause bone resorption, to reconstitute the biological space, which may compromise the final aesthetic result [16].

It should also be considered that the vestibular bone crest reabsorbs vertically, during the healing process [17]. This resorption process may be a consequence of the decrease in blood supply to the bone plate due to the folding of the mucoperiosteal flap [18]. Another factor to be evaluated after installing the immediate implant is the horizontal bone defect, also called the gap.

Therefore, based on these aspects and directions, the present study aimed to conduct a systematic review of the main approaches to tooth extraction associated with immediate implantation in the aesthetic area.

2. Methods

2.1. Study Design

The present study followed a concise systematic review model, following the rules of systematic review - PRISMA (Transparent reporting of systematic reviews and meta-analysis-<http://www.prisma-statement.org/>) [19].

2.2. Data sources and research strategy

The search strategy was carried out in the PubMed, Embase, Ovid, Cochrane Library, Web Of Science, and Scopus databases, using descriptors: Exodontics; Immediate dental implant; Dental extraction; Minimally traumatic extraction; Aesthetics, and the use of Booleans "and" among descriptors and "or" among historical findings.

2.3. Study quality and risk of bias

The quality of the studies was based on the GRADE instrument [20] and the risk of bias was analyzed according to the Cochrane instrument [21].

3. Results and Discussion

A total of 134 studies were found that were submitted to the eligibility analysis and, after that, 38 studies of high to medium quality and with risks of bias were selected that do not compromise the scientific basis of the studies (Figure 1). As a result, after a complete analysis of these selected studies on extraction associated with immediate implantation in the aesthetic area, it became evident that the extraction of a tooth initiates a series of reparative processes involving hard tissue (alveolar bone) and soft tissue (periodontal ligament), gingiva) [22]. The bone healing process involves the inflammatory, reparative, and remodeling phases. The first stage is characterized by the formation of the clot, the second by the construction of the bone callus and the third is the remodeling and formation of new lamellar bone tissue.

In this sense, after tooth extraction, the alveolus is filled with blood and the formation of a blood clot occurs [23]. Within the first week after tooth removal, the blood clot that filled the socket is almost completely remodeled and replaced with granulation tissue. After a week of tissue modeling, the deposition of mineral tissue begins [24]. After 2-4 weeks, erythrocytes dispersed between mesenchymal cells can still be observed. In this healing phase, the granulation tissue and a fibrous temporary matrix represent the dominant tissues, constituting an average of 30% and 50%, respectively, of the total tissue that is filling the alveolus [25].

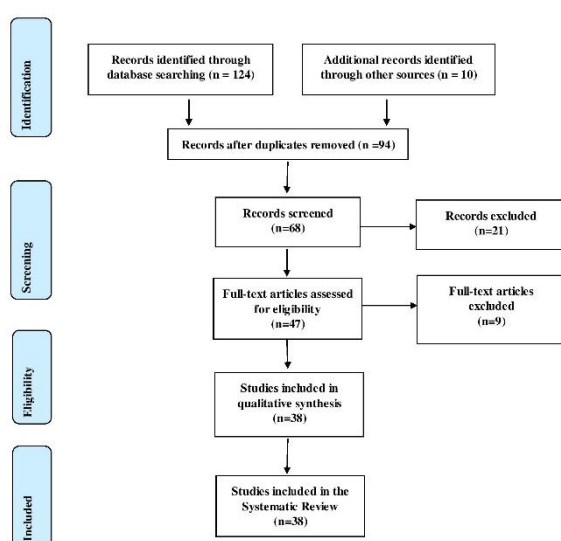


Figure 1. Eligibility of studies.

After that, 6-8 weeks of healing, most of the granulation tissue is replaced by the temporary fibrous

matrix and bone tissue, and the marginal part of the alveolus anchors islands of immature bone tissue [24-26]. Even at this stage, the fibrous provisional matrix and bone tissue have been shown to occupy about 60% and 35% of the tissue [25]. These tissues are also predominantly demonstrated at a later stage of healing (12-24 weeks), while the lamellar and medullary bone is often less observed and represented. Thus, bone organization and architecture are generally incomplete within 24 weeks after tooth extraction [22].

3.1. Minimally Traumatic Extraction (MTE) and Aesthetics

All extractions must be performed with a precise indication, because of defined prosthetic planning. In addition, they should be as painless, safe, and comfortable as possible. Thus, new management and extraction techniques have been tested and employed [1-3].

In this sense, in therapy with dental implants, the need to preserve the largest amount of alveolar bone possible is of great importance. The placement of implants right after extraction has been much discussed in recent years, due to persistent clinical failures and also the vestibular bone loss caused by extraction itself. These challenges need to be overcome and new technologies are emerging to meet these needs [4]. In prominence, when the rehabilitation with implants is in an aesthetic region, the procedure requires greater care and becomes more complex, in addition to generally having a greater expectation from the patient [27,28].

In this regard, it is known that for the successful placement of implants or any other type of dental prosthesis, it depends on several factors, and among them is MTE. New methods for this purpose are emerging and being well accepted, as they propose better preservation of the bone crest, reduction of bone loss in width and thickness, and conservation of the vestibular bone board, making the aesthetic result to be optimized [4].

One of the alternatives of MTE is the use of membranes and grafts, used to preserve or recover bone volume after tooth extraction, whether in height or width of the alveolar crest, as well as to compensate for any type of bone loss due to trauma [29]. However, these techniques have the disadvantage of increasing the cost, morbidity, and treatment time, in

addition to making implant placement with immediate loading unviable [30].

Also, another method found in the literature that enters the context of minimal bone intervention is the exfoliation of the teeth using orthodontic rubber bands. The method offers a gradual removal of the tooth and is more conservative than the dental extractor, however, like the grafting and membranes techniques, it has the disadvantage of requiring longer treatment time, with an average extraction time of six weeks [30, 31]. For patients using bisphosphonates for MTE, it seems to decrease the severity of postoperative complications, as bone loss is reduced with this technique [30,32].

In this context, the various techniques for MTE have as main objective the preservation of the buccal alveolar bone and maintenance of gingival contour after tooth extraction. As examples, there are the periostomes, blade of bivers, and dental extractors [5,33-36]. The periostome is a surgical instrument that works by separating the periodontal ligament from the tooth. The instrument is placed in the groove between the periodontal ligament and the tooth, the entire circumference of the tooth is contoured. The periostome most often reaches the fibers of the cervical and middle third. After the separation of the periodontal ligament and the tooth, extraction proceeds with conventional instruments such as levers and forceps in an atraumatic manner [33]. The bivers blade, similarly to the periostome, aims to break the fibers of the periodontal ligament, facilitating the removal of the tooth with levers and/or forceps.

Besides, tooth extractors perform extraction in the vertical direction, promoting an MTE [5,27,35,36]. In this sense, the main indications for dental extractors are when immediate implants will be performed, especially in aesthetic areas and fractured teeth below the gingival margin, because with the use of the screw inserted in the residual root, flaps and osteotomy can be avoided. In addition, dental extractors can be used on any multi-root or single-root teeth that are not in the context of contraindications, including fractured roots, non-retained tooth extractor screw, hypercementosis, root divergence in multi-root teeth, and root lacerations [5,35].

In this sense, the authors tested a dental extractor to verify its applicability and limitations [5]. Among the teeth to be extracted with the extractor, only 17% were unsuccessful, the causes of failures were the impossibility of retaining the screw inserted in the tooth to be extracted, macroglossia making it

difficult to use the appliance, fractured roots, and hypercementosis. Also, a study analyzed the mechanism of action of vertical extractors, using the three-dimensional finite element method, observing the tensile and compressive forces that the dental extractor can cause in the alveolus of the tooth to be extracted. The results found were that the dental extractor favors traction pressures and reduces compressive forces. In addition, the traction pressure develops predominantly at the apex of the alveolus and decreases with the proximity of the cervical. These findings support the idea of MTE offered by the device [37].

In this sense, as another example, a study with 48 patients analyzed implants in sites with healed bone (control group) and alveoli after extraction (test group). In the test group, a gap less than or equal to 2mm occurred between the bone wall and the implant surface, while in the control group, the bone cortex was in direct contact with the implant. Membranes or filling materials were not used in the surgical sites, which, during healing, were covered by soft tissue. After 12 months of healing, histological analysis was performed and it was noted that the degree of bone in contact with the implant in all samples was high, between 62 and 71%, and there were no differences between the control group and the control group. test. The authors demonstrate that the hard tissue can fill and occupy the marginal defects around the implant, in extraction sites, during healing, and that the vestibular and palatal portions of the bone crest after tooth removal suffer more loss of horizontal tissue and less vertical tissue loss [38].

Still, a case report study showed the application of the immediate dentoalveolar restoration technique to reconstruct the buccal bone wall, with an autogenous graft from the maxillary tuberosity, which had been lost by root fracture, and provide the necessary bone substrate for the installation of an implant and its provisioning. One of the greatest risks inherent in the survival of immediate implants is the maintenance of their stability during the healing period. In this case, due to a mechanical trauma in sports activity in the first postoperative month, there was a complete failure in the osseointegration process, confirmed by tomographic examination of both the implant and the bone graft. The deleterious effects of this accident were compensated with a new approach and reapplication of the immediate dentoalveolar restoration technique with a smaller diameter implant and with conical macro geometry in conjunction with the new bone reconstruction under the same

compromised socket; associated, after the period of osseointegration, with maneuvers to increase the volume of gingival tissue by subepithelial connective tissue graft. The tomographic result demonstrated the success of the surgical procedures, and the clinical/photographic analysis obtained showed the stability of the gingival margin without compromising the aesthetic result of the prosthetic restoration [39].

In addition, a prospective multicenter cohort study was carried out to identify implant risk factors, complications, and patient-centered results after immediate implant placement in a single tooth and loading in aesthetic areas. Immediate consecutive implants placed in incisors, canines, and premolar sites were included. Data from 215 implants in 215 patients were collected at 15 centers in 2 years. Potential risk factors were identified in 116 patients (54.21%). There were 11 dropouts after 1 year and 37 after 2 years. Failures were relatively frequent (14.6%) before delivery of the definitive prosthesis. No significant association was observed between early failures and risk factors. One failure and six recessions were observed after the definitive prosthesis. High satisfaction scores were recorded in 2 years. No recession occurred in the risk-free group. Five cases of mucositis and one case of peri-implantitis were observed in the 2-year follow-up [40].

Finally, a study analyzed the result of immediate post-extraction implants placed with and without bone graft in the maxillary premolar area for 3-year follow-up after loading at the aesthetic level. After tooth extraction, 102 patients received 115 immediate dental implants. After 3 years, 1 implant failed in each group. Thirty-seven patients had inflammation and bleeding, 19 mucosities, and 2 peri-implantitis. The level of the mesial bone was -0.61 mm in group B (with a bone graft) and -1.01 mm in group A. The distal bone level in group B was -0.71 mm and -1.12 mm in group A. The average vestibular probing in Group B was increased (+0.40 mm) than in group A (+0.36 mm). The average palatal value of group B was higher (+0.54 mm) than group A (+0.38 mm). No statistically significant difference was found between the 2 groups. However, the Pink Esthetic Score and patient satisfaction were higher in group B than in A ($p < 0.001$). Therefore, the use of an inorganic bovine bone substitute with a resorbable collagen barrier in immediate post-extractive implants seems to improve the aesthetic results after 3 years of follow-up [41].

4. Conclusion

According to the main literary findings, the use of the technique of installing immediate implants, after extraction, requires planning and care in the management of soft tissues, to correct aesthetic sequelae. The use of precise and minimally traumatic techniques enabled satisfactory and functional aesthetic results, as well as improving the patient's aesthetics and self-esteem. The immediate implant placement procedure after tooth extraction preserves bone height and thickness, reduces treatment time and cost, in addition to maintaining the gingival architecture, being important for the aesthetic success of future prosthetic rehabilitation. Also, it presents success rates comparable to implants in fully healed edges, the extraction must be done in a minimally traumatic way, to preserve the maximum bone tissue. The horizontal defects present after the installation of the immediate implant (gaps), if they are less than or equal to 3mm, will heal with complete bone filling. However, if they are larger than 3mm, bone graft material and/or membrane should be used so that there is bone healing.

References

- [1] B. Suprakash, A. Y. Ahammed, A. Thareja, R. Kandaswamy, N. Kumar, S. Bhondwe, Knowledge and attitude of patients toward dental implants as an option for replacement of missing teeth, *The journal of contemporary dental practice*, 14 (2013) 115-118. [\[DOI\]](#) [\[PubMed\]](#)
- [2] S.D.C.S. Sardinha, P.R.L. Viana, E. Azoubel, B.R.G. Pinheiro, Levantamento epidemiológico realizado na clínica de cirurgia bucal, *Revista Odonto Ciência*, 21 (2006) 227-231.
- [3] G.G. Zafiroopoulos, A. Kasaj, O. Hoffmann, Immediate implant placement in fresh mandibular molar extraction socket: 8-year results, A case report. *Journal of Oral Implantology*, 36 (2010) 145-151. [\[DOI\]](#) [\[PubMed\]](#)
- [4] D. Saund, T. Dietrich, Minimally invasive tooth extraction doorknobs and strings revisited, *Dental Update, Dental update*, 40 (2013) 325-330. [\[DOI\]](#) [\[PubMed\]](#)
- [5] E. Muska, C. Walter, A. Knight, P. Taneja, Y. Bulsara, M. Hahn, M. Desai, T. Dietrich, Atraumatic vertical tooth extraction: a proof of principle clinical study of a novel system, *Oral surgery, oral medicine, oral pathology and oral radiology*, 116 (2013) 303-310. [\[DOI\]](#) [\[PubMed\]](#)
- [6] H.P. Hornig, T. Offermann, Implant preparation: atraumatic tooth extraction using easy X Trac system tooth extractor, *Dental*

- Products Report, 7 (2005) 68-69.
- [7] C.E. Misch, (2000) *Implantes dentários contemporâneos*, Santos, São Paulo.
- [8] H.W. Denissen, W. Kalk, Preventive implantations, *International dental journal*, 41 (1991) 17-24. [[PubMed](#)]
- [9] D.A. Gelb, (1991) Alteration of protocol to enhance esthetic and functional results of osseointegrated implants, In Annual Meeting of the American Academy of Periodontology.
- [10] S.L. Wheeler, R.E. Vogel, R. Casellini, Tissue preservation and maintenance of optimum esthetics: a clinical report, *International Journal of Oral & Maxillofacial Implants*, 15 (2000) 265-271. [[PubMed](#)]
- [11] L. Schropp, L. Kostopoulos, A. Wenzel Bone healing following immediate versus delayed placement of titanium implants into extraction sockets: a prospective clinical study, *International Journal of Oral & Maxillofacial Implants*, 18 (2003) 189-199. [[DOI](#)] [[PubMed](#)]
- [12] J. Lindhe, T. Karring, (2005) *E LANG, NP Tratado de Periodontia Clínica e Implantologia Oral*, Guanabara Koogan S, Rio de Janeiro.
- [13] B. Wagenberg, S.J. Froum, A retrospective study of 1925 consecutively placed immediate implants from 1988 to 2004, *International Journal of Oral & Maxillofacial Implants*, 21 (2006) 71-80. [[PubMed](#)]
- [14] B.E. Becker, W. Becker, A. Ricci, N.A. Geurs prospective clinical trial of endosseous screw-shaped implants placed at the time of tooth extraction without augmentation, *Journal of Periodontology*, 69 (1998) 920-926. [[DOI](#)] [[PubMed](#)]
- [15] D.A. Gelb, Immediate implant surgery: three-year retrospective evaluation of 50 consecutive cases, *International Journal of Oral & Maxillofacial Implants*, 8 (1993) 388-399. [[PubMed](#)]
- [16] M.A. Bianchini, (2000) *O passo a passo cirúrgico na Implantodontia: da instalação à prótese*, Santos.
- [17] R. Adell, U. Lekholm, B. Rockler, P.I. Branemark, A 15-year study of osseointegrated implants in the treatment of the edentulous jaw, *International journal of oral surgery*, 10 (1981) 387-416. [[DOI](#)] [[PubMed](#)]
- [18] J.C. Kois, J.Y. Kan, Predictable peri-implant gingival aesthetics: surgical and prosthodontic rationales, *Pract Proced Aesthet Dent*, 13 (2001) 691-698. [[PubMed](#)]
- [19] D. Moher, A. Liberati, J, Tetzlaff D.G. Altman, The PRISMA Group, Preferred Reporting Items for Systematic Reviews and Meta-Analyses: The PRISMA Statement, *PLoS Medicine*, 6 (2009). [[DOI](#)] [[PubMed](#)]
- [20] H. Balshem, M. Helfand, H.J. Schünemann, A.D. Oxman, R. Kunz, J. Brozek, G. E. Vist, Y. F. Ytter, J. Meerpoh, S. Norris, G. H. Guyatt, Grade guidelines: 3 rating the quality of evidence, *Journal of clinical epidemiology*, 64 (2011) 401-406. [[Doi](#)] [[PubMed](#)]
- [21] J. Higgins, S. Green, (2011) *Cochrane Handbook for Systematic Reviews of Interventions*, Version 5.1.0, The Cochrane Collaboration.
- [22] R. Farina, L. Trombelli, Wound healing of extraction sockets, *Endodontic Topics*, 25 (2011) 16-43. [[DOI](#)]
- [23] M.H. Amler, The time sequence of tissue regeneration in human extraction wounds, *Oral Surgery, Oral Medicine, Oral Pathology*, 27 (1969) 309-318. [[DOI](#)] [[PubMed](#)]
- [24] M.H. Amler, P.L. Johnson, I. Salman, Histological and histochemical investigation of human alveolar socket healing in undisturbed extraction wounds, *The journal of the american dental association*, 61 (1960) 32-44. [[DOI](#)] [[PubMed](#)]
- [25] L. Trombelli, R. Farina, A. Marzola, L. Bozzi, B. Liljenberg, J. Lindhe, Modeling and remodeling of human extraction sockets, *Journal of clinical periodontology*, 35 (2008) 630-639. [[DOI](#)] [[PubMed](#)]
- [26] C.I. Evian, E. S. Rosenberg, J.G. Coslet, H. Corn, The osteogenic activity of bone removed from healing extraction sockets in humans, *Journal of Periodontology*, 53 (1982) 81-85. [[DOI](#)] [[PubMed](#)]
- [27] Thomé, G. et al. Indicações e limitações do uso do extrator dentário. *J. ILAPEO, [S. l.]*, v. 6, n. 2, p. 85-88, abr./maio 2012.
- [28] A. S. Nogueira, B.C. do Egito Vasconcelos, R. Frota, Á.B. Cardoso, (2006) *Orientações pós-operatórias em cirurgia bucal*, *Revisão De Literatura*, 1-6
- [29] M. Salomao, F.K. Alvarez, J.T.T. Siqueira, Regeneração óssea guiada em defeitos extensos pós-exodontias utilizando membrana exposta ao meio bucal, *ImplantNews*, 7 (2010) 753-759.
- [30] A.A. Oghli, H. Steveling, Ridge preservation following tooth extraction: a comparison between atraumatic extraction and socket seal surgery, *Quintessence International*, 41 (2009) 605-609. [[PubMed](#)]
- [31] E. Regev, J. Lustmann, R. Nashef, Atraumatic

- teeth extraction in bisphosphonate-treated patients, *Journal of oral and maxillofacial surgery*, 66 (2008) 1157-1161. [DOI] [PubMed]
- [32] L. Schropp, A. Wenzel, L. Kostopoulos, T. Karring, Bone healing and soft tissue contour changes following single-tooth extraction: a clinical and radiographic 12-month prospective study, *International Journal of Periodontics & Restorative Dentistry*, 23 (2003) 213-323. [PubMed]
- [33] H. Dym, A. Weiss, Exodontia: Tips and Techniques for Better Outcomes, *Dental Clinics*, 56 (2012) 245-266. [DOI] [PubMed]
- [34] A. Oliveira, J. Souza, G. Thomé, A. C. Melo, I. Sartori, Implante imediato unitário em função imediata—relato de caso, *Revista da Faculdade de Odontologia-UPF*, 13 (2008) 70-74. [DOI]
- [35] C.A.A. Babbush, New atraumatic system for tooth removal and immediate implant restoration, *Implant dentistry*, 16 (2007) 139-145. [DOI] [PubMed]
- [36] D.R. Meneses, Exodontiaatraumática e previsibilidade em reabilitação oral com implantes osseointegráveis: relato de casos clínicos aplicando o Sistema Brasileiro de Exodontia Atraumática Xt Lifting®, *Revista portuguesa de estomatologia, Medicina Dentaria e cirurgia maxilofacial*, 50 (2009) 11-17. [DOI]
- [37] S.J. Jayme, P.R. Ramalho, L.D. Franco, R.E. Jugdar, J.A. Shibli, M.A. Vasco, Análise 3D por elementos finitos e descrição de dois casos clínicos sobre o uso de extrator dentário vertical para diminuir o trauma ósseo, *ImplantNews*, 10 (2013) 193-200.
- [38] M. Paolantonio, M. Dolci, A. Scarano, D. d'Archivio, G. Di Placido, V. Tumini, A. Piattelli, Immediate implantation in fresh extraction sockets. A controlled clinical and histological study in man, *Journal of periodontology*, 72 (2001) 1560-1571. [DOI] [PubMed]
- [39] R.D.L. Franceschi, L. Drechsel, G. Schuldt Filho, Application of Immediate Dentoalveolar Restoration in Alveolus Compromised with Loss of Immediate Implant in Esthetic Area, *Case reports in dentistry*, (2018). [DOI] [PubMed]
- [40] C. Clauser, N.M. Sforza, I. Menini, Z. Kalemaj, J. Buti, Collaborators of Accademia Toscana di Ricerca Odontostomatologica (ATRO) IPI Group, Immediate Postextraction Single-Tooth Implants and Provisional Crowns in the Esthetic Area: 2-year Results of a Cohort Prospective Multicenter Study- Patient-Centered Outcomes, *International Journal of Oral & Maxillofacial Implants*, 35 (2020) 833-840. [DOI] [PubMed]
- [41] F. Mastrangelo, G. Gastaldi, R. Vinci, G. Troiano, L. Tettamanti, E. Gherlone, L.L. Muzio, Immediate Postextractive Implants With and Without Bone Graft: 3-year Follow-up Results From a Multicenter Controlled Randomized Trial, *Implant dentistry*, 27 (2018) 638-645. [DOI] [PubMed]

Acknowledgement

Nil

Funding

Not applicable

Data sharing statement

No additional data are available

Ethics Approval

Approval was sought and granted by the Departmental Ethics Committee.

Informed consent

Informed written consent obtained from the participant

Conflict of interest

The authors declare no conflict of interest.

About The License

© The author(s) 2021. The text of this article is open access and licensed under a Creative Commons Attribution 4.0 International License