



Methods for Removing Fractured Endodontic Instruments in Root Canal : A Brief Systematic Review

Taís da Silva Lima ^{1,2}, Lara Biliato Alves ^{1,2}, Fábio Pereira Linhares de Castro ^{1,2,*}

¹ University Center North Paulista (Unorp) - Sao Jose do Rio Preto, Sao Paulo, Brazil.

² Post graduate and continuing education (Unipos), Sao Jose do Rio Preto, Sao Paulo, Brazil.

*Corresponding author Email: linharendodontia@hotmail.com

DOI: <https://doi.org/10.34256/mdnt2134>

Received: 14-05-2021; Accepted: 02-06-2021; Published: 10-06-2021

Abstract: Introduction: In the scenario of endodontic treatment, fracture of the instrument complicates the endodontic procedure by obstructing debridement, delaying the completion of treatment, and affecting the patient's dental experience. When a file fractures during root canal treatment, several treatment options are available. Fractured endodontic instruments inhibit optimal cleaning and filling of root canals. **Objective:** To carry out a brief systematic review study to present the main clinical outcomes of different types of techniques for removing fragments of endodontic instruments in root canals. **Methods:** The rules of the Systematic Review-PRISMA Platform were followed. The research was carried out from November 2020 to January 2021 and developed based on Scopus, PubMed, and SCIENCE DIRECT. The quality of the studies was based on the GRADE instrument and the risk of bias was analyzed according to the Cochrane instrument. **Results:** A total of 132 articles were found involving the removal of fragments of endodontic instruments. A total of 80 articles were evaluated in full and 30 were included and evaluated in the present study. It has been found that the probability of successful removal of a fractured instrument is reported to range from 53 to 95%, with more than 80% of fractured instruments being removed by the use of ultrasound. Also, long fragments (0.4 mm) can adsorb ultrasonic energy and hinder its loosening. Nickel-titanium (NiTi) instruments with their pseudo-elasticity, especially the newly developed heat-treated NiTi instruments are more ductile and flexible compared to conventional NiTi2. **Conclusion:** Fractured instruments can be removed by a variety of methods, such as good ultrasonic tips, microtubule devices, and hemostatic pliers/forceps. Removing a fractured file is associated with considerable risk, and therefore the fragment must be circumvented. A cost-benefit analysis of the treatment should be considered before selecting a definitive treatment for the patient.

Keywords: Endodontic treatment, Fractures, Instruments, Root cana, Fragment removal

1. Introduction

In the scenario of endodontic treatment, fracture of the instrument complicates the endodontic procedure by obstructing debridement, delaying the completion of treatment, and affecting the patient's dental experience. When a file breaks, several treatment options can be selected, however, future management should be based on the effect of the fractured instrument on the treatment outcome. Within the limits of the literature, it appears that retained fractured instruments do not reduce the prognosis of teeth treated endodontically if apical periodontitis is absent; however, if the disease is present, healing is significantly reduced. Therefore, the stage at which an instrument fracture in infected cases seems likely to be significant, as disinfection of the canal will be compromised accordingly [1].

When a file fractures during root canal treatment, several treatment options are available. Definitive management should be based on a thorough understanding of the success rates for each treatment option, balanced with the potential risks of file removal or retention. Although the integration of modern techniques with endodontic practice has improved the clinician's ability to remove fractured files, removal is not always possible or even desirable. Therefore, in cases without apical disease, removal of the file may not be necessary and retention or deviation should be considered. If there is an apical disease, the file fracture significantly reduces the prognosis, indicating a greater need for attempted removal of the file or deviation. The removal of a fractured file presents considerable risks, especially in the apical regions of the root canal, therefore, leaving the fragment in situ should be considered if a referral is not possible [2].

In this context, fractured endodontic instruments inhibit optimal cleaning and filling of the root canals, resulting in a less favorable prognosis for the tooth. Various techniques are available to remove fractured instruments, however, the substance of the healthy tooth must often be destroyed in the process. Thus, Nd: YAG laser treatment is a method to remove fractured stainless steel instruments without destroying the substance of the healthy tooth. Fractured endodontic instruments can be successfully removed in 77.3% of cases [3].

Also, there is an alternative method with the use of the SureFil SDR for photopolymerization (Dentsply, York, PA) to the use of cyanoacrylate for the removal of fractured endodontic instruments using the tube technique. In general, studies have shown that the use of photopolymerizable composites within the microtube is superior in comparison to the use of cyanoacrylate [4,5].

Besides, the success rate of standardized techniques with the aid of a surgical microscope to remove or bypass fractured instruments from root canals has been shown to considerably increase the visualization of the fractured instrument, up to a 2-fold increase, with a success rate of around 47, 7% to 85.3% [6].

Besides, the fracture of nickel-titanium rotary files is a real concern among endodontists and may affect the long-term treatment prognosis. In this sense, ultrasound is a favorable technique for removing fragments from instruments, although it can result in some complications. The ultrasonic technique can exhibit an 80% success rate in removing these fragments. Also, the success rate for roots with a file fracture before the curve was 11.5 times higher than in cases of file fracture beyond the curve. Studies have also shown that the average time required for the removal of lime fragments was 36.3 ± 7.15 minutes, which did not differ significantly in different lime locations within the channel. Also, the ultrasonic application has been shown not to significantly affect the force required for root fracture [7,8,9].

Thus, most endodontists prefer to remove the pins instead of performing periapical surgery. Few root fractures have been reported. Ultrasonic vibration was the most common method used to remove pins from all types of teeth, with the Egger pin remover most commonly used for pins in anterior teeth [8-10].

Finally, as measures to track these instrument fractures in root canals, periapical radiographs (RPs)

and cone-beam computed tomography (CBCT) stand out for dentists' decision-making in diagnosis and treatment. In general, TCFC observers decide to remove and circumvent the fractured fragment, while RP observers decide to leave the fragments in situ [11].

Therefore, the present study aimed to conduct a brief systematic review study to present the main clinical outcomes of different types of techniques to remove fragments of endodontic instruments.

2. Methods

2.1. Study Design

The rules of the Systematic Review-PRISMA Platform (Transparent reporting of systematic reviews and meta-analysis-HTTP: [//www.prisma-statement.org/](http://www.prisma-statement.org/)) were followed [12].

2.2. Data sources and research strategy

The search strategies for this systematic review were based on the keywords (MeSH Terms): "Endodontic treatment; Fractures; Instruments; Root canal; Fragment removal". The research was carried out in November 2020 to January 2021 and developed based on SCOPUS (Elsevier and non-Elsevier database), PUBMED (MEDLINE biomedical literature, life science magazines, and online books), and SCIENCE DIRECT (Elsevier database), including the National Institutes of Health RePORTER Grant database and clinical trial records. Also, a combination of the keywords with the booleans "OR", AND and the operator "NOT" were used to target the scientific articles of interest. The title and abstracts were examined under all conditions.

2.3. Study quality and risk of bias

The quality of the studies was based on the GRADE instrument [13] and the risk of bias was analyzed according to the Cochrane instrument [14]. Two independent reviewers (1 and 2) carried out research and study selection. Data extraction was performed by reviewer 1 and fully reviewed by reviewer 2. A third investigator decided on some conflicting points and made the final decision to choose the articles. Only studies reported in Portuguese and English have been evaluated.

3. Results and Discussion

A total of 132 articles were found involving the removal of fragments of endodontic instruments. Initially, duplication of articles was excluded. After this process, the abstracts were evaluated and a new exclusion was performed, removing articles that did not include the theme of this article. A total of 80 articles were evaluated in full and 30 were included and evaluated in the present study (Figure 1).

Considering the Cochrane tool for risk of bias, the overall assessment resulted in 5 studies with a high risk of bias and 3 studies with uncertain risk. The domains that presented the highest risk of bias were related to the number of participants in each study addressed, and the uncertain risk was related to the safety and efficacy of the techniques for removing fragments from endodontic instruments. Also, there was an absence of the source of funding in 4 studies and 3 studies did not disclose information about the conflict of interest statement.

After a thorough analysis of these selected studies, it was found that the probability of successful removal of a fractured instrument is reported to range from 53 to 95% [15-17], with more than 80% of fractured instruments being removed by the use of ultrasound, but cementation techniques are useful in cases where ultrasonic techniques fail. Also, long fragments (0.4 mm) can adsorb ultrasonic energy and hinder its loosening. Nickel-titanium (NiTi) instruments with their pseudo-elasticity, especially the newly developed heat-treated NiTi instruments are more ductile and flexible compared to conventional NiTi2.

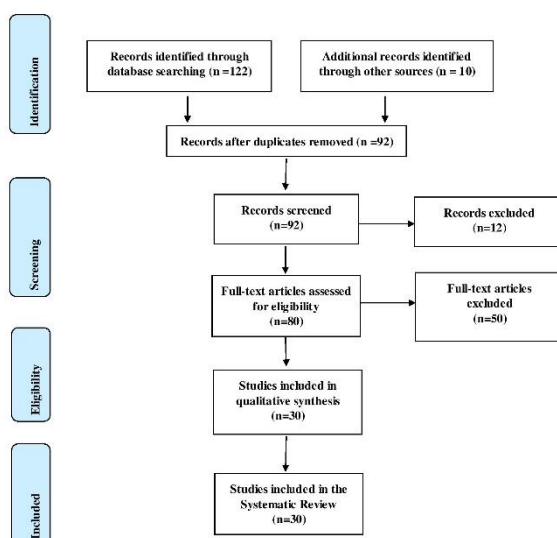


Figure 1. Flow Chart of Study Eligibility.

In general, NiTi's low yield and tensile strength compared to stainless steel instruments are claimed to increase fracture susceptibility at lower loads, but current developments in manufacturing processes [18], especially heat treatment has led to an increase in instrument longevity, and fractures can occur more rarely. However, even with this development, they do not completely prevent fractures of the instrument [19].

Also, when using a modified tube technique with light-curing composite, recommendations should be followed to ensure that higher fault loads, such as avoiding creating an inverted conical cone when exposing the instrument, a regular conical or parallel shape allows for greater tearing of the forces, ensure complete adjustment of the composite curing light (depending on the exposure time and light intensity) and use a bonding agent to increase adhesion and to achieve maximum pullout force [19].

Also, a recent systematic review and meta-analysis analyzed the endodontic result when an instrument was retained in the root canal system. It was concluded that a retained fractured instrument does not significantly reduce the prognosis of endodontic treatment in the absence of periodontitis, but that a fractured instrument in the presence of apical periodontitis reduced the prognosis. This corroborated several studies of general results relating to apical periodontitis and success [20-22], suggesting that the influence of a fractured file on the disinfection of the canal was small, as long as the treatment was carried out according to the highest technical standard. What is difficult to establish from these studies is the additional influence of fractured files on teeth with apical periodontitis, as the presence of apical disease is already a negative prognostic factor [23,24].

This systematic review is based on only two case-control studies with a 35-year interval [23,24]. Randomized clinical trials are uncommon in endodontics and they are impossible to conduct in the fracture area of root canal endodontic instruments, where randomization is impossible [2]. Besides, the included studies were carried out in dental hospitals and specialized practices, which are subpopulations; this can limit extrapolation to general dental practice.

Also, other studies have shown that retained fractured instruments reduce prognosis [26,27]. The first published study on the impact of retained fractured instruments reported a 19% reduction in healing rate when a fractured instrument was present [26]. However, this study included only 15 cases of

fractured instruments, and incomplete radiographic scarring was classified as unsuccessful; however, the observation period was long at 4-10 years. Subsequent studies have also reported a negative effect of an instrument fragment retained on the endodontic result, but only in the presence of a necrotic pulp or when a periapical lesion was present [28,29]. These older studies, published before the introduction of the NiTi files, may have limited relevance to the current practice of endodontics. Recent publications have indicated that the presence of a preoperative apical radiolucency is a more significant prognostic factor than a fractured instrument.

Also, extrapolation of root canal filling within 0-2 mm of the radiographic apex has been significantly associated with an increase in the success of endodontic treatment and since a retained instrument is likely to prevent this, success will be consequently reduced, however, this does not have been demonstrated conclusively in the literature.

Therefore, to eliminate the influence of the filling on the canal walls, the fracture resistance test without filling was performed. It was found that the ultrasonic removal of the fractured instrument from the middle third of the channels significantly decreased the resistance of the vertical fracture of the channel. Souter and Messer [30] stated that the removal of the fractured instrument from the middle third of the channels decreased the root resistance by 30% about the strength in the control group. Madarati *et al.* [31] and Gerek *et al.* [32] also found that this procedure decreased the resistance of the root fracture.

However, these findings are inconsistent with the findings of Shahabinejad *et al.* [33], who found that the force required for root fracture is not related to the location of the fractured instrument. This can be attributed to differences related to sample selection, application of force, and the use of filling between the different studies.

4. Conclusion

Fractured instruments can be removed by a variety of methods, such as good ultrasonic tips, microtubule devices, and hemostatic pliers/forceps. These techniques require qualified use of the operating microscope. Removing a fractured file is associated with considerable risk, and therefore the fragment must be circumvented. Removing fractured instruments can be expensive in terms of time and equipment and therefore, a cost-benefit analysis of the treatment must be considered before selecting a definitive treatment for the patient.

References

- [1] M.B. McGuigan, C. Louca, H.F. Duncan, The impact of fractured endodontic instruments on treatment outcome, *British dental journal*, 214 (2013) 285-289. [[DOI](#)] [[PubMed](#)]
- [2] M.B. McGuigan, C. Louca, H.F. Duncan, Clinical decision-making after endodontic instrument fracture, *British dental journal*, 214 (2013) 395-400. [[DOI](#)] [[PubMed](#)]
- [3] B. Cvikl, J. Klimscha, M. Holly, M. Zeitlinger, R. Gruber, A. Moritz, Removal of fractured endodontic instruments using an Nd:YAG laser, *Quintessence international*, 45 (2014) 569-75. [[Doi](#)] [[PubMed](#)]
- [4] M. Wefelmeier, M. Eveslage, S. Bürklein K. Ott, M. Kaup, Removing fractured endodontic instruments with a modified tube technique using a light-curing composite, *Journal of endodontics*, 41 (2015) 733-736. [[DOI](#)] [[PubMed](#)]
- [5] M. Brühl, K. Urban, D. Donnermeyer, E Schäfer, S. Bürklein, Tube Technique with Light-curing Composite for Removing Fractured Root Canal Instruments: Influence of Polymerization Cycles and Mechanical Exposure, *Journal of endodontics*, 46 (2020) 425-430. [[DOI](#)] [[PubMed](#)]
- [6] G. Nevaes, R.S. Cunha, M.L. Zuolo, C.E. Bueno, Success rates for removing or bypassing fractured instruments: a prospective clinical study, *Journal of endodontics*, 38 (2012) 442-444. [[DOI](#)] [[PubMed](#)]
- [7] H. Shahabinejad, A. Ghassemi, L. Pishbin, A. Shahravan, Success of ultrasonic technique in removing fractured rotary nickel-titanium endodontic instruments from root canals and its effect on the required force for root fracture, *Journal of Endodontics*, 39 (2013) 824-828. [[DOI](#)] [[PubMed](#)]
- [8] T. Castrisos, P.V. Abbott, A survey of methods used for post removal in specialist endodontic practice, *International endodontic journal*, 35 (2002) 172-180. [[DOI](#)] [[PubMed](#)]
- [9] A. Cruz, C.G. Mercado-Soto, I. Ceja, L.G. Gascón, P. Cholico, C.A. Palafox-Sánchez, Removal of an instrument fractured by ultrasound and the instrument removal system under visual magnification, *The journal of contemporary dental practice*, 16 (2015) 238-242. [[DOI](#)] [[PubMed](#)]
- [10] M. Fu, X. Huang, K. Zhang, B. Hou, Effects of Ultrasonic Removal of Fractured Files from the Middle Third of Root Canals on the Resistance to Vertical Root Fracture, *Journal of endodontics*, 45 (2019) 1365-1370. [[DOI](#)] [[PubMed](#)]

- [11] S.Y. Özer, G. Ozkan, E. Çetin, H.D. Özkan, A comparative study of cone-beam computed tomography and periapical radiographs in decision-making after endodontic instrument fractures, *The International journal of artificial organs*, 40 (2017) 510-514. [DOI] [PubMed]
- [12] D. Moher, A. Liberati, J. Tetzlaff, D.G. Altman, The PRISMA Group, Preferred Reporting Items for Systematic Reviews and Meta-Analyses: The PRISMA Statement, *PLOS Medicine*, 6 (2009). [DOI] [PubMed]
- [13] H. Balshem, M. Helfand, H.J. Schünemann, A.D. Oxman, R. Kunz, J. Brozek, G.E. Vist, Y. Falck-Ytter, J. Meerpohl, S. Norris, G.H. Guyatt, Grade guidelines: 3 rating the quality of evidence, *Journal of clinical epidemiology*, 64 (2011) 401-406. [DOI] [PubMed]
- [14] J. Higgins, S. Green, (2011) *Cochrane Handbook for Systematic Reviews of Interventions*, Version 5.1.0, The Cochrane Collaboration.
- [15] Y. Shen, B. Peng, G. Shun-pan, G.S. Chueng, Factors associated with the removal of fractured NiTi instruments from root canal systems, *Oral Surgery, Oral Medicine, Oral Pathology, Oral Radiology, and Endodontology*, 98 (2004) 605-610. [DOI] [PubMed]
- [16] N J Souter, Messer H. Complications associated with fractured file removal using an ultrasonic technique, *Journal of Endodontics*, 31 (2005) 450-452. [DOI] [PubMed]
- [17] J. Cujé, C. Bargholz, M. Húlsman, The outcome of retained instrument removal in a specialist practice, *International endodontic journal*, 43 (2010) 545-554. [DOI] [PubMed]
- [18] A. Madarati, A. J. Qualtrough, D.C. Watts, Vertical fracture resistance of roots after ultrasonic removal of fractured instruments, *International endodontic journal*, 43 (2010) 424-429. [DOI] [PubMed]
- [19] J. Saunders, P. Eleazer, P. Zhang, S. Michalek, Effect of a separated instrument on bacterial penetration of obturated root canals, *Journal of endodontics*, 30 (2004) 177-179. [DOI] [PubMed]
- [20] U. Sjögren, B. Hagglund, G. Sunqvist, K. Wing Factors affecting the long-term results of endodontic treatment, *Journal of endodontics*, 16 (1990) 498-504. [DOI] [PubMed]
- [21] Y.L. Ng, V. Mann, S. Rahbaran, J. Lewsey, K. Gulabivala, Outcome of primary root canal treatment: systematic review of the literature – Part 2, Influence of clinical factors. *International endodontic journal*, 41 (2008) 6-31. [DOI] [PubMed]
- [22] Y.L. Ng, V. Mann, K. Gulabivala, Outcome of secondary root canal treatment: a systematic review of the literature, *International endodontic journal*, 41 (2008) 1026-1046. [DOI] [PubMed]
- [23] M.C. Crump, E. Natkin Relationship of a broken root canal instruments to endodontic case prognosis: a clinical investigation, *The Journal of the American Dental Association*, 80 (1970) 1341-1347. [DOI] [PubMed]
- [24] M. C. Crump, E. Natkin, Relationship of a broken root canal instrument to endodontic case prognosis: a clinical investigation, *The Journal of the American Dental Association*, 80 (1970) 1341-1347. [DOI] [PubMed]
- [25] P. Panitvisai, P Parunnit, C. Sathorn, H.H. Messer, Impact of a retained instrument on treatment outcome: a systematic and meta-analysis, *Journal of endodontics*, 36 (2010) 775-780. [DOI] [PubMed]
- [26] L Z. Strindberg, The dependence of the results of pulp therapy on certain factors: an analytical study based on radiographic and clinical follow-up examination, *Acta Odontol Scand*, 14, (1956) 1-175.
- [27] K. Kerekes, L. Tronstad, Long-term results of endodontic treatment performed with a standardized technique, *Journal of endodontics*, 5 (1979) 83-90. [DOI] [PubMed]
- [28] Y. Terauchi, L. OLeary, I. Kikuchi, M. Asanagi, T. Yoshioka, C. Kobayashi, H. Suda, Evaluation of the efficiency of a new file removal system in comparison with two conventional systems, *Journal of endodontics* 33 (2007) 585–587. [DOI] [PubMed]
- [29] L.I. Grossman, Guidelines for the prevention of fracture of root canal instruments, *Oral Surgery, Oral Medicine, Oral Pathology*, 28 (5) 746-752. [DOI] [PubMed]
- [30] N.J. Souter H. H.Messer, Complications associated with fractured file removal using an ultrasonic technique, *Journal of Endodontics*, 31 (2005) 450-452. [DOI] [PubMed]
- [31] A.A. Madarati, A.J. Qualtrough, D.C. Watts, Vertical fracture resistance of roots after ultrasonic removal of fractured instruments, *International endodontic journal*, 43 (2010) 424-429. [DOI] [PubMed]
- [32] M. Gerek, E.D. Baser, M.B. Kayahan, H. Sunay, R.F. Kaptan, G. Bayırlı, Comparison of the force required to fracture roots vertically after ultrasonic and Masserann removal of broken instruments, *International endodontic journal*, 45 (2012) 429-434. [DOI] [PubMed]
- [33] H. Shahabinejad, A. Ghassemi, L. Pishbin, A.

Shahravan, Success of ultrasonic technique in removing fractured rotary nickel-titanium endodontic instruments from root canals and its effect on the required force for root fracture, *Journal of Endodontics*, 39 (2013) 824-828. [[DOI](#)] [[PubMed](#)]

Acknowledgement

Nil

Funding

Not applicable

Data sharing statement

No additional data are available

Conflict of interest

The authors declare no conflict of interest.

About The License

© The author(s) 2021. The text of this article is open access and licensed under a Creative Commons Attribution 4.0 International License